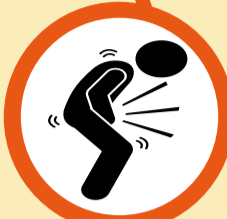



Standard Treatment Workflow (STW) for the Management of PAEDIATRIC ABDOMINAL TUBERCULOSIS ICD-10-A18.31

WHEN TO SUSPECT?

- Presence of Fever >2 weeks
 - Anorexia
 - Unexplained weight loss* or no weight gain in last 3 months
 - History of contact with TB patient
 - With one or more of following
 - › Recurrent/chronic abdominal pain in presence of red flag signs
 - › Abdominal distension/mass
 - › Altered bowel habits
- *Constitutional symptoms may or may not be present in suspected case of Abdominal TB



CLINICAL FEATURES SPECIFIC TO TYPE OF ABDOMINAL TB

PERITONEAL TB	VISCERAL TB (LIVER, SPLEEN, PANCREAS)
<ul style="list-style-type: none"> • Abdominal pain, distension • Fever • Weight loss 	<ul style="list-style-type: none"> • Abdominal pain • Fever • Jaundice • Weight loss • Anorexia
NODAL TB	
<ul style="list-style-type: none"> • Pain abdomen • Fever • Palpable abdominal lump 	
INTESTINAL TB	
<ul style="list-style-type: none"> • Recurrent intestinal colic • Altered bowel habits • Chronic diarrhoea • Partial/complete intestinal obstruction • Weight loss, anorexia • Palpable abdominal lump • Lower gastrointestinal bleeding 	<ul style="list-style-type: none"> • Hepatomegaly • Splenomegaly • Hepatic abscess • Palpable abdominal lump • Abnormal LFTs

EXAMINATION FINDINGS

- Anthropometry
- General physical & systemic examination
- Look for peripheral LAP, ascites, hepatosplenomegaly, doughy feel of abdomen, palpable abdominal lump, visible peristalsis

RED FLAGS

- Pain abdomen waking child from sleep
- Chronic, severe, or nocturnal diarrhea
- Gastrointestinal blood loss
- Localized distension or mass

INVESTIGATIONS

ESSENTIAL

- Ultrasound abdomen

SPECIFIC FINDINGS

- Abdominal LN : measuring >15 mm in short axis, conglomerate and/or central necrosis
- Omental/mesenteric thickening >15 mm with increased echogenicity
- Ileocaecal wall thickening

NON SPECIFIC FINDINGS

- Intraabdominal fluid (free or loculated) or Inter-loop ascites
- Ascitic fluid with multiple septations
- Abdominal LAP with SAD <15 mm in absence of red flag signs

Ascites

Essential

- If exudative ascites, ascitic fluid for NAAT, TB culture
- No role of ADA

Enlarged Abdominal LN (SAD>15 mm)

Desirable

- USG guided Abdominal LN-FNA for cytology, NAAT, TB culture

Optional

- USG/CT guided core biopsy of LN for histology, NAAT, TB culture

Intestinal involvement

Desirable

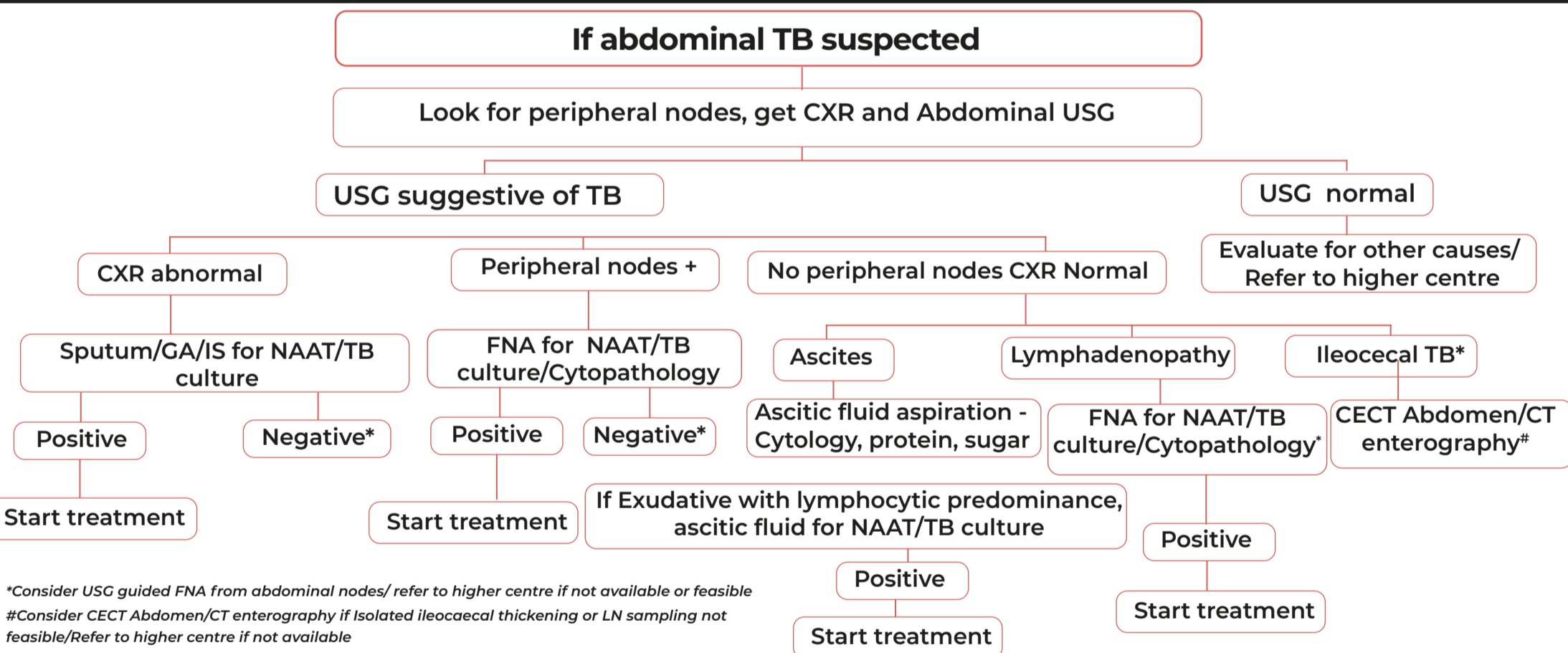
- If Ileocaecal thickening with enlarged nearby LN
- USG guided Abdominal LN-FNA for cytology, NAAT, culture
- Isolated ileocaecal thickening/LN sampling not feasible
- CECT Abdomen/CT enterography

Optional

- Ileocolonoscopy, tissue biopsy (HPE, NAAT)
- Laparoscopy, tissue biopsy for HPE, NAAT

- Chest X Ray
- sputum/GA/IS (If CXR abnormal) for NAAT, TB culture
- Ascitic fluid (If present) for cytology, protein & albumin
- Peripheral LN-FNA (If size >2 cm) for cytology, NAAT, TB culture

DIAGNOSTIC ALGORITHM



*Consider USG guided FNA from abdominal nodes/ refer to higher centre if not available or feasible
#Consider CECT Abdomen/CT enterography if Isolated ileocaecal thickening or LN sampling not feasible/Refer to higher centre if not available

MANAGEMENT

TREATMENT

- Start treatment & follow-up as per NTEP
- ATT for 6 months (2HRZE + 4HRE)
- Pyridoxine supplementation- 10 mg/day
- Steroids- not useful & not recommended
- Supportive treatment- Management of SAM/Malnutrition as per national guidelines
- Surgical treatment:
 - › Acute intestinal obstruction, Bowel perforation
 - › Persistence of obstructive symptoms despite conservative management & ATT
- DO NOT start Empirical ATT with isolated:
 - › Recurrent/Chronic abdominal pain without red flag signs
 - › Chronic diarrhoea without proper evaluation
 - › Failure to gain weight

MONITORING

- **Assessment of response to treatment:**
 - › Clinical follow up - every month during treatment & after that every 3 months
 - › Radiologically by USG - At the end of treatment or if worsening or non response to treatment
 - › Microbiological - If worsening or non response to treatment
- **Pointers towards DR TB investigation:**
 - › Non response to treatment or Worsening or deterioration of constitutional symptoms after initial improvement. Consider possibility of Inflammatory Bowel disease after ruling out Crohn's disease
- **Obstructive symptoms may persist or worsen despite treatment with ATT**
- **Monitor for**
 - › Adherence to treatment (ATT)
 - › Adverse drug reactions- ATT induced

WHEN TO REFER?

- Diagnosis is uncertain & additional investigations are required
- Acute intestinal obstruction or bowel perforation
- DR TB
- No response to appropriate treatment
- Oral drug (ATT) intolerance/cannot be given

ABBREVIATIONS

ATT- Antitubercular treatment	E- Ethambutol	IS- Induced Sputum	R- Rifampicin
CECT- Contrast Enhanced Computed Tomography	FNA- Fine Needle Aspiration	LAP- Lymphadenopathy	SAD- Sagittal Abdominal Diameter
CT- Computed Tomography	GA- Gastric Aspirate	LN- Lymph Node	SAM- Severe Acute Malnutrition
CXR- Chest X-Ray	H- Isoniazid	MGIT- Mycobacteria Growth Indicator Tube	USG- Ultrasonography
DR-TB- Drug Resistant tuberculosis	HPE- Histopathological Examination	NAAT- Nucleic Acid Amplification Test	Z- Pyrazinamide

REFERENCES

1. National TB Elimination Programme, Central TB Division. Training Modules for Programme Managers & Medical Officers. Ministry of Health & Family Welfare, Government of India. <https://tbcindia.gov.in/index1.php?lang=1&level=1&sublinkid=5465&lid=3540> Last access on 10 March, 2022.
2. Guidelines for programmatic management of drug resistant tuberculosis in India March 2021. National TB Elimination Programme, Central TB Division, Ministry of Health & Family Welfare, Government of India accessed at <https://tbcindia.gov.in/showfile.php?lid=3590> Last access on 10 March, 2022.