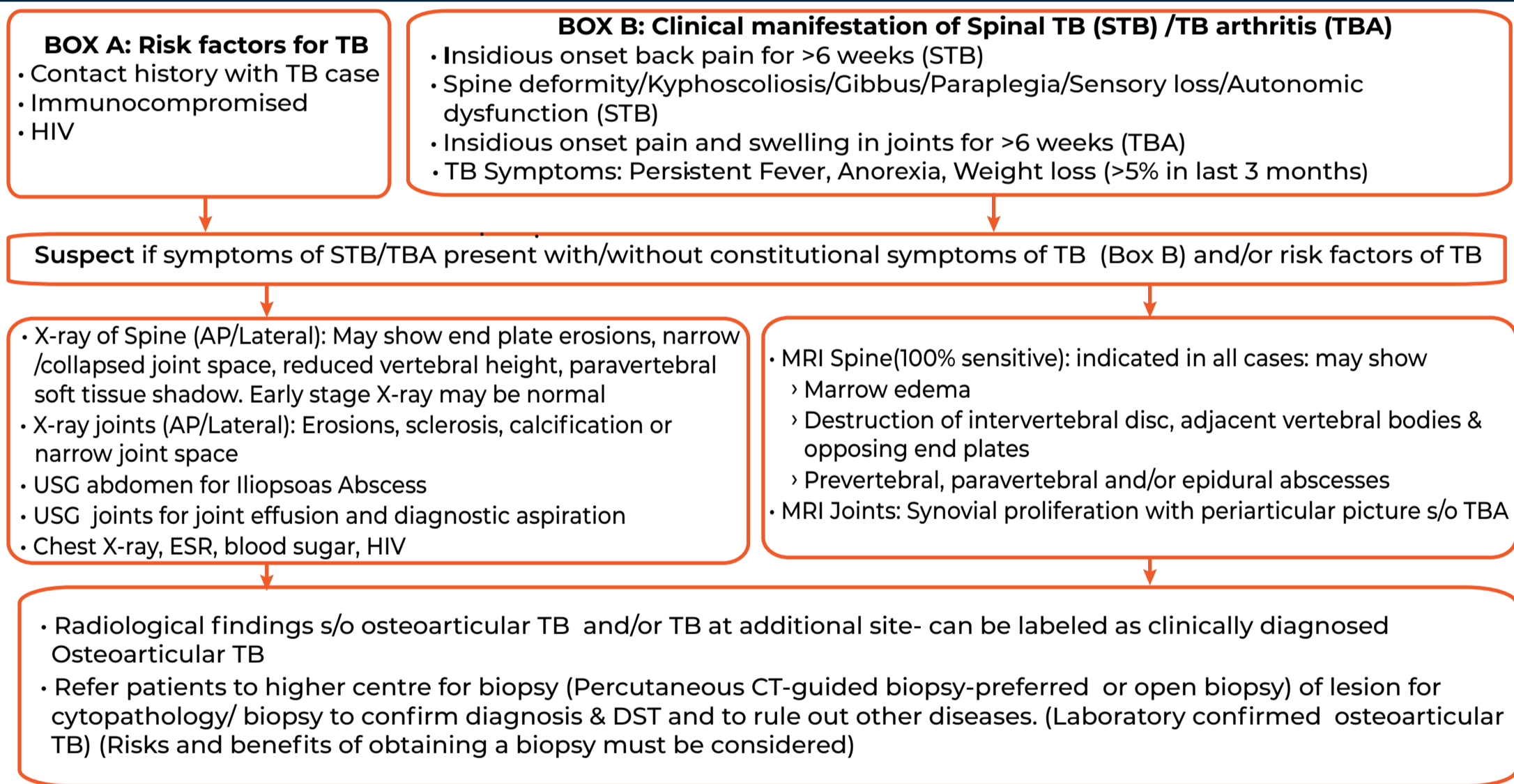




Standard Treatment Workflow (STW) for the Management of PAEDIATRIC OSTEOARTICULAR TUBERCULOSIS ICD-10-18.0

	POTT'S SPINE (COMMONEST, 50% OF OSTEOARTICULAR TB)	DACTYLITIS (SHORT BONES)	ARTHRITIS (LARGE JOINTS-HIP/KNEE COMMONEST)
WHEN TO SUSPECT	<ul style="list-style-type: none"> Insidious onset back pain for >6 weeks (Commonest thoracic > lumbar > cervical) Localized/Referred root pain TB Symptoms: Fever/anorexia/weight loss CNS complications like Paraparesis (20-50%), cauda equina syndrome, paraspinal muscle wasting, severe pain Examination: Local tenderness/deformity 	<ul style="list-style-type: none"> Swelling of short tubular bones of hands & feet (Proximal phalanx or metacarpals of index/middle/ring fingers are commonly affected) In children multiple or consecutive bones are involved, compared to a single bone in adults May present without pyrexia or signs of inflammation 	<ul style="list-style-type: none"> Insidious onset joint pain, swelling Monoarticular arthritis Commonly associated with pulmonary or lymph node TB
INVESTIGATION	<p>ESSENTIAL</p> <ul style="list-style-type: none"> X-ray Spine <ul style="list-style-type: none"> In early stage X-ray may be normal May show end plate erosions, joint space narrowing/collapse, decreased vertebral height, paravertebral soft tissue shadow MRI Spine preferred, if not feasible do CT <ul style="list-style-type: none"> Marrow edema Destruction of intervertebral disc, adjacent vertebral bodies & opposing end plates Pre/para vertebral or epidural abscess Sputum/GA for NAAT, MGIT/LJ (if CXR abnormal) FNAC (if peripheral lymphnodes enlarged) for Cytology, NAAT & MGIT/LJ <p>DESIRABLE</p> <ul style="list-style-type: none"> Image guided (USG/CT) aspiration of abscess (if feasible) for NAAT & MGIT/LJ. 	<p>ESSENTIAL</p> <ul style="list-style-type: none"> Plain X-ray of involved parts <ul style="list-style-type: none"> Diaphyseal expansile lesion Periosteal reaction is uncommon Healing is by sclerosis (usually gradual) X-ray film of chest <ul style="list-style-type: none"> Sputum/GA for NAAT & MGIT/LJ, if CXR abnormal FNAC (if peripheral lymphnodes enlarged) for Cytology, NAAT & MGIT/LJ <p>DESIRABLE</p> <ul style="list-style-type: none"> Image guided (USG/CT) aspirate from involved bones for NAAT & MGIT/LJ. 	<p>ESSENTIAL</p> <ul style="list-style-type: none"> Plain X-ray: A triad of X-ray abnormalities (Phemister's triad) includes <ul style="list-style-type: none"> Peri-articular osteoporosis Peripherally located osseous erosion Gradual joint space narrowing Early stage synovitis & arthritis imaging may show wide joint space due to effusion Bony ankylosis development is rare in TB arthritis in contrast to Pyogenic arthritis USG/ MRI of joint X-ray film of chest Sputum/GA for NAAT, MGIT (if CXR abnormal) FNAC (if peripheral lymphnodes enlarged) for Cytology, NAAT & MGIT/LJ <p>DESIRABLE</p> <ul style="list-style-type: none"> Image guided (USG/CT) aspirate from joint fluid for NAAT & MGIT/LJ.

DIAGNOSTIC ALGORITHM



MANAGEMENT

TREATMENT & MONTORING

- Start treatment for microbiologically /Lab confirmed TB and probable TB
- Regimen : 2HRZE + 10HRE (Standard doses) + Pyridoxine 10 mg/day
- Follow up every month during treatment & subsequently every 3 months: Pott's spine with X-ray or MRI & Tubercular dactylitis or arthritis with plain X-ray
- Monitor on each visit :
 - Symptomatic improvement, weight gain, side effects of medicines
 - Microbiology : sputum/GA if CXR abnormal at end of IP. Site samples like aspiration of pus from lesions including psoas abscess (if worsening of symptoms/poor response)
- Imaging: MRI/CT/X ray of affected parts: at end of treatment or early if worsening

Surgical Indications in Potts Spine

- Progressive neurological deficit
- Paraplegia of recent onset or severe paraplegia
- Persistent pain with spinal instability
- Spinal deformity-severe kyphotic deformity at presentation, or in children (<10 years of age) at high risk of progression of kyphosis with growth after healing of disease

WHEN TO REFER

- Suspected osteoarticular disease if essential investigations are not available
- Diagnosis (microbiological or probable) not established by investigations
- Surgery needed: imaging suggest compressive myelopathy, motor deficits
- No improvement with appropriate treatment
- DR TB : diagnosed or high suspicion

Confirm microbiologically in all cases, if possible, before ATT

OTHER INFORMATION

- In case of synovial fluid or cold abscess aspiration (against gravity), send samples for confirmation of TB in following 3 ways
 - Two dry slide for demonstration of AFB (ZN staining)
 - Two samples in formalin for histopathological examination
 - Two samples in saline for culture followed by DST and/or NAAT
- Confirmed cases to undergo HIV/blood sugar testing/parent counselling *MGIT/LJ (if MGIT not available)

ABBREVIATIONS

AFB: Acid fast bacillus	DST: Drug Sensitivity Test	HRZE: Isoniazid; Rifampicin; Pyrazinamide; Ethambutol	NAAT: Nucleic Acid Amplification Test
AP: Antero-Posterior	ESR: Erythrocyte Sedimentation Rate	IP: Intensive Phase	s/o: Suggestive of
CT: Computed Tomography	FNAC: Fine Needle Aspiration Cytology	LJ: Lowenstein Jensen	STB: Spinal TB
CXR: Chest X-ray	GA: Gastric Aspirate	MGIT: Mycobacteria Growth Indicator Tube	TBA: TB Arthritis
DR: Drug Resistant TB	HIV: Human Immunodeficiency Virus	MRI: Magnetic Resonance Imaging	USG: Ultrasonography
			ZN: Ziehl Neelson

REFERENCES

- National TB Elimination Programme, Central TB Division. Training Modules for Programme Managers & Medical Officers. Ministry of Health & Family Welfare, Government of India. <https://tbcindia.gov.in/index1.php?lang=1&level=1&sublinkid=5465&lid=3540> Last access on 12 March, 2022.
- Guidelines for programmatic management of drug resistant tuberculosis in India March 2021. National TB Elimination Programme, Central TB Division, Ministry of Health & Family Welfare, Government of India accessed at <https://tbcindia.gov.in/showfile.php?lid=3590> Last access on 12 March, 2022.
- Sharma SK, Ryan H, Khaparde S, Sachdeva KS, Singh AD, Mohan A, et al., Index-TB guidelines: guidelines on extrapulmonary tuberculosis for India, Indian J Med Res. 2017;145(4):448-6